

A prospective comparative study of USG guided fascia Iliaca block with INJ bupivacaine and dexmedetomidine v/s INJ bupivacaine for positioning and postoperative analgesia in patients with intertrochanteric fracture posted for closed reduction and internal fixation under regional anaesthesia

Anish Sharma NG^{1*}, Kaustubha Devi A²

¹ Associate professor, Department of Anesthesiology, KVG medical colleges and hospital, sullia, Karnataka, India

² Postgraduate, Department of Anesthesiology, KVG medical college sullia, Karnataka, India

* Corresponding Author: Anish Sharma NG

Abstract

Introduction: Positioning intertrochanteric fracture cases for subarachnoid block is challenging. Fascia iliaca compartment block (FICB) helps in positioning and provides analgesia.

AIM: To study and compare FICB with inj bupivacaine with dexmedetomidine (DMT) and inj bupivacaine with regard to:

1. Positioning of patient during subarachnoid block
2. Duration of postoperative analgesia.

Methods: After obtaining approval from institutional ethics committee and written informed consent from the patient, 120 patients aged between 30-80 years belonging to American Society of Anaesthesiologist class 1 and 2 scheduled for closed reduction and internal fixation for intertrochanteric fracture were allocated into two groups.

Group A received FICB with inj. bupivacaine 0.25% of 20ml and inj. DMT 0.5µg/kg and Group B received FICB with inj. bupivacaine 0.25% of 20ml.

Onset and duration of analgesia were recorded in terms of VAS.

Data were analyzed using SPSS 22.0 software and t-test was used as test of significance and P <0.05 was considered as statistically significant.

Results: In group A, mean VAS score at 10 min was 5.39±0.61 and in group B it was 6.46±0.50, similarly at 15min mean VAS score in group A was 1.49±0.50 and in group B it was 5.36±0.51.

Mean time for rescue analgesia in group A was 407.5±20.13 and in group B was 291.91±18.81 which was significant.

Conclusion: Fascia iliaca compartment block with dexmedetomidine reduces the duration of onset of Block and significantly prolongs the duration of analgesia.

Keywords: intertrochanteric fracture, fascia iliaca block, dexmedetomidine, positioning, postoperative analgesia, vas (visual analogue score)

Introduction

Patients with Inter trochanteric fracture are challenging to anesthesiologist as positioning for subarachnoid block is often difficult as they experience severe pain on minimal movement [1]. Ultrasound guided Fascia iliaca compartment block has been used effectively for providing analgesia during positioning and also in prolonging the duration of postoperative analgesia [2]. Perineural dexmedetomidine in combination with bupivacaine enhances sensory and motor block without neurotoxicity in experimental studies.

Materials and Methods

Source of Data: All patients aged between 30-80 years of age undergoing CRIF for IT fracture in the Department of Anaesthesiology in KVG medical college, sullia from January 2019 to December 2019 was included in the study.

Study Design: Prospective study.

Inclusion Criteria

- ASA grade 1 and 2 patients.
- Patients aged between 30-80 years of age.

Exclusion Criteria

- Patient refusal.
- Coagulation disorders.
- Infection over injection site.
- Contraindications for FICB.

Sample Size: A total of 120 patients with 60 in each group.

$$n = 2\sigma^2 \frac{(Z_{1-\alpha} + Z_{1-\beta})^2}{(\mu_1 - \mu_2)^2}$$

Statistical Analysis

MS Excel and SPSS version 22.0 was used to analyse data and T test was used to find out the statistical difference between the two groups.

Methodology

After obtaining approval from the Institutional Ethics Committee and written informed consent from the patient, the study was conducted. A day prior, preoperative visit was

made and thorough clinical evaluation was conducted and necessary investigations was ordered and reviewed. Written informed consent was taken for the procedure.

After shifting patients to preoperative room, baseline heart rate (HR), blood pressure, mean arterial pressure (MAP), oxygen saturation (SpO2) visual analogue score, bromage score was recorded. Patients was randomly allocated into two groups by a computer-generated table. Group A Recieved FICB with injection bupivacaine 0.25% 30 cc with injection dexmedetomidine 0.5 µg/kg and Group B received FICB with injection bupivacaine 0.25% 30 cc. Ultrasound guided fascia iliaca compartment block was given and vitals recorded. Sensory block, Bromage score, VAS score and Ramsay sedation scores was recorded.

Patients were positioned for subarachnoid block once VAS score was <2. After administration of subarachnoid block, vitals were recorded every 5 min till the completion of surgery. After surgery, patients were shifted to postanesthesia care unit and hemodynamics monitored.

At Post anaesthesia care unit- vitals, bromage score, VAS, RSS, sensory block levels were assessed and recorded every 20 min till Bromage score was 0. Sensory block was assessed every 1 hr for 24 hrs. The time to first postoperative rescue analgesia as evidenced by VAS ≥4 was noted and rescue analgesia in the form of injection tramadol 1.5mg/kg was administered IV. At the end of study, patient satisfaction score was recorded. Sedation was assessed using Ramsay's Sedation Score.

Results

MS excel and MS word were used to obtain various graphs. MS excel and SPSS version22.0 were used to analyse data and t test was used to find a significant statistical difference between the two groups. P<0.05 was considered statistically significant. VAS score was significantly high in group B than in group A at 10 and 15 mins. Mean time for rescue analgesia was statistically significant in group A (407.5 ± 20.13) compared to group B (291.91 ± 18.18). Mean patient satisfaction score was statistically significant in group A than group B. The difference in mean Ramsay sedation score in two groups was not statistically significant. The difference in the Heart rate and mean arterial pressure was not statistically significant in two groups.

Discussion

Intertrochanteric fracture is a very painful condition perioperatively, which is further exaggerated by movements. Intravenous analgesics have their limitations because of their adverse effects and its interaction with other drugs. Fascia iliaca compartment block is a simple method which requires minimal instrumentation with few absolute contraindications. Ultrasound guidance improves visualization, success rates, quality of sensory block and onset time and decreases dose of local anaesthetics. Fascia iliaca compartment block is highly recommended for pain control in patients with IT fracture as it helps in positioning the patient for subarachnoid block, reduces pain, time for rescue analgesia, Need for systemic analgesics and shortens the duartion of hospital stay. A study conducted by Gopal *et al* [3] on 60 fracture femur cases concluded that Fascia iliaca compartment block ensured patient comfort during positioning for Subarachnoid block and provided postoperative analgesia. Dexmedetomidine significantly prolongs postoperative analgesia. A study conducted by

Agarwal *et al* [4] on 50 patients posted for upper limb surgeries were enrolled for a prospective, randomized, double-blind, placebo-controlled trial. They concluded that dexmedetomidine added as an adjuvant to bupivacaine for supraclavicular brachial plexus block significantly shortened the onset time and prolongs the duration of sensory and motor blocks and duration of analgesia.

A study conducted by esmaoglu *et al* [5] on 60 patients scheduled for elective forearm and hand surgeries concluded that dexmedetomidine added to levobupivacaine for axillary brachial plexus block shortens the onset time and prolongs the duration of the block and the duration of postoperative analgesia.

A study conducted by Swami *et al* [6] on 60 American society of anaesthesiologist I and II patients scheduled for elective upper limb surgeries under supraclavicular brachial plexus block concluded that dexmedetomidine when added to local anaesthetic in supraclavicular brachial plexus block enhanced the duration of sensory and motor block and also the duration of analgesia. The time for rescue analgesia was prolonged in patients receiving dexmedetomidine.

Table 1: Visual Analog Scale Score comparison between two groups

VAS score	Group A	Group B	P Value
	Mean ± SD	Mean ± SD	
5 min	7.49 ± 0.50	7.48 ± 0.50	0.9130
10 min	5.39 ± 0.61	6.46 ± 0.50	<0.0001
15 min	1.49 ± 0.50	5.36 ± 0.51	<0.0001
20 min	0 ± 0	4.2 ± 0.63	NA
25 min	0 ± 0	1.48 ± 0.50	NA

Table 2: Difference in time to rescue analgesia between the two groups

Time to Rescue Analgesia	Group A	Group B	P Value
VAS > 2 HOURS	307.58 ± 15.44	241.83 ± 16.41	<0.0001
VAS > 4 HOURS	407.5 ± 20.13	291.91 ± 18.18	<0.0001

Table 3: Patient Satisfaction Score between the two groups.

Patient Satisfaction Score	Group A	Group B	P Value
	3.37 ± 0.48	2.47 ± 0.50	<0.0001

Table 4: Ramsay Sedation Score between the two groups.

Ramsay Sedation Score	Group A	Group B	P Value
	2.13 ± 0.42	2.10 ± 0.44	0.7031

Table 5: Ramsay Sedation Score.

1	Patient is anxious, agitated, or restless
2	Patient is cooperative, oriented, and tranquil alert
3	Patient responds to commands
4	Asleep, but with brisk response to light glabellar tap or loud auditory stimulus
5	Asleep, sluggish response to light glabellar tap or loud auditory stimulus
6	Asleep, no response

Table 6: Visual Analogue Score.

Pain intensity	Word scale
0	No pain
1-2	Least pain
3-4	Mild pain
5-6	Moderate pain
7-8	Severe pain
>9	Excruciating pain

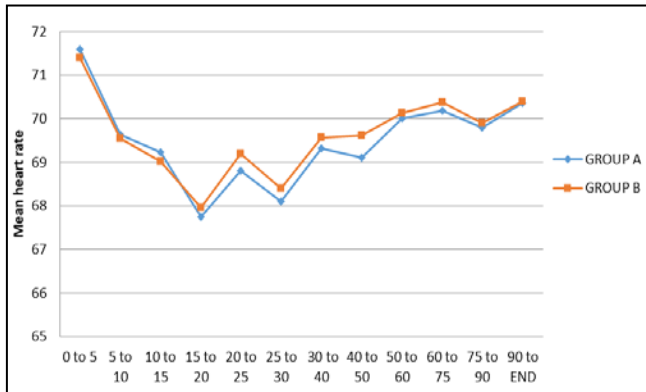


Fig 1: Comparison of heart rate between the two groups

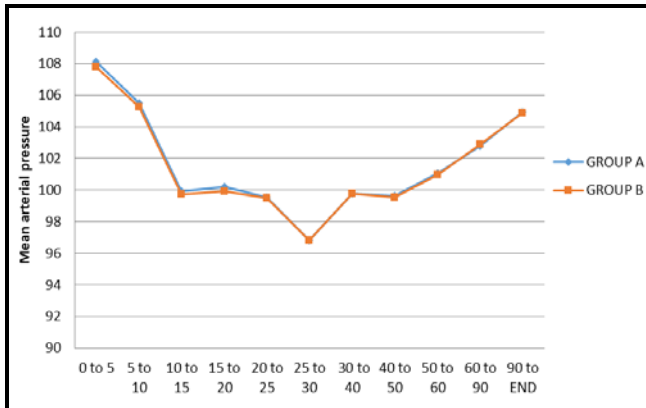


Fig 2: Comparison of mean arterial pressure between the two groups

Conclusion

Fascia iliaca compartment block is safe, easy to perform and provides effective analgesia without any haemodynamic instability.

From our study, FICB done prior to Subarachnoid block was found to ensure the following:

- Patient comfort during positioning for subarachnoid block and also provides postoperative analgesia.
- Addition of dexmedetomidine to bupivacaine 0.25% reduces the time for onset of block and significantly prolongs postoperative analgesia when compared to plain bupivacaine.

References

- Adams HA, Saatweber P, Schmitz CS, Hecker H. Postoperative pain management in orthopaedic patients: no differences in pain score, but improved stress control by epidural anaesthesia. *Eur J Anaesthesiol.* 2002; 19:658-65.
- Foss NB, Kristensen BB, Bundgaard M, Bak M, Heiring C, Virkelyst C, *et al.* Fascia iliaca compartment blockade for acute pain control in hip fracture patients. *Anesthesiology.* 2007; 106:773-7.
- Gopal ND, Krishnamurthy D, A Clinical Comparative Study of Fascia Iliaca Compartment Block with Bupivacaine and Bupivacaine with Dexmedetomidine for Positioning and Duration of Postoperative Analgesia in Fracture Femur under Spinal Anesthesia. *Anesth Essays Res.* 2018; 12(2):528-534. Doi: 10.4103/aer.AER_56_18
- Agarwal S, Aggarwal R, Gupta P. Dexmedetomidine prolongs the effect of bupivacaine in supraclavicular

brachial plexus block. *J Anaesthesiol Clin Pharmacol.* 2014; 30:36-40.

- Esmaoglu A, Yegenoglu F, Akin A, Turk CY. Dexmedetomidine added to levobupivacaine prolongs axillary brachial plexus block. *Anesth Analg.* 2010; 111:1548-51.
- Swami SS, Keniya VM, Ladi SD, Rao R. Comparison of dexmedetomidine and clonidine (α_2 agonist drugs) as an adjuvant to local anaesthesia in supraclavicular brachial plexus block: A randomised double-blind prospective study. *Indian J Anaesth.* 2012; 56:243-9.