



## Report of an unidentified haemoflagellate from human blood sample

Sanjay Karlekar<sup>1\*</sup>, Satish Pawar<sup>2</sup>, Archana Patil<sup>3</sup>, Vitthal Zare<sup>4</sup>, Mukund Deshpande<sup>5</sup>, Raymond Andrew<sup>6</sup>

<sup>1</sup> Research cum Training Center, Shradhanandpeth, Nagpur, Maharashtra, India

<sup>2</sup> Commissionrate of Health Services, Arogya Bhavan, Mumbai, Maharashtra, India

<sup>3</sup> Directorate of Health Services, Rajya Kutumb Kalyan, Pune, Maharashtra, India

<sup>4</sup> Assistant Director Health Services (Malaria), Nagpur, Maharashtra, India

<sup>5</sup> Assistant Director Health Services (Malaria), Arogya Bhavan, Pune, Maharashtra, India

<sup>6</sup> Centre for Higher learning and Research in Zoology, Hislop College, Nagpur, Maharashtra, India

### Abstract

**Background & Objective:** Nature of the work is an accidental discovery of new Haemoflagellate in human blood sample.

**Methods:** Finger prick blood sample collected stained with JSB I and JSB II for malaria microscopy, declared negative for malaria parasite. Cross checked for malaria parasite.

**Results:** Unidentified haemoflagellate detected in blood sample exhibited new morphological structure than known.

**Interpretation & Conclusions:** Known uni-flagellate protozoa in humans are Trypanosoma and Leishmania. Trypanosoma observed in mastigote form with undulating membrane while Leishmania remain oval amastigote form in humans. The newly identified haemoflagellate has cup shaped morphology with a single flagellum. It resembles the characteristics of family Trypanosomatidae. The life cycle, vector, host and disease caused by this haemoflagellate are unknown.

**Keywords:** haemoflagellate, mastigote, protozoa, trypanosomatidae

### Introduction

Haemoflagellate protozoans belong to the family Trypanosomatidae is composed of six genera, namely; *Leptomonas*, *Herpetomonas*, *Blastocrithidia*, *Crithidia*, *Trypanosoma* and *Leishmania*. Human haemoflagellates belongs to the genus *Trypanosoma* and *Leishmania*. The morphological forms of family Trypanosomatidae from all six genera possess the following forms: amastigote (leishmanial), choanomastigote, promastigote (leptomonad), opisthomastigote (trypanomorphic), epimastigote (crithidial) and trypomastigote (trypanosomatid). In human blood, *Trypanosoma* is found in trypomastigote form with undulating membrane while *Leishmania* is found in amastigote form. The morphology of these forms has been well documented [1, 6].

### Material and Method

The finger prick blood sample of the patient was collected by Auxillary Nurse Midwife (ANM) during the fever survey for the detection of malaria parasite. The collected sample was stained with JSB I and JSB II and examined by concerned laboratory technician at PHC level. This sample was cross checked at the office of the Assistant Director Health Services (Malaria), Nagpur [7]. Photographs and video of the sample was taken during microscopy with the help of Cat-cam microscope.

The photographs of the haemoflagellate protozoa were sent to the Zoonosis laboratory of National Communicable Disease Centre (NCDC) New Delhi, Microbiology department of Indira Gandhi Medical College (IGMC), Nagpur and Government Veterinary College, Nagpur for identification with other known form of haemoflagellates.

The microbiology department reported that this specimen appears new and belongs to the category of unidentified haemoflagellate.

### Patient Details (based on verbal autopsy)

The patient, aged 60 years, occupation-farmer, had a history of intermittent fever, headache, vomiting and weakness for about 11 days in July 2012. His blood sample was collected by Auxillary Nurse Midwife of PHC for malaria parasite, stained and declared negative for malaria parasite. This sample was cross checked at the office of the Assistant Director Health Services (Malaria), Nagpur, as per the guideline of National Vector Borne Disease Control Programme<sup>7</sup>. Repeated samples of blood of the patient were collected for further investigation. Patient resides in mud plastered house, non-alcoholic, vegetarian and tobacco chewer. The patient usually does not take any medicine for his minor sickness. No other member of his family was ill during that period.

### Results

The incidental nature of this discovery is underscored by the fact that, the blood sample of patient was collected during the fever survey for the detection of malaria parasite. During the process of cross checking for the detection of malaria parasite an unusual different flagellate was observed by the main author (SRK) in the blood sample.

### Morphology

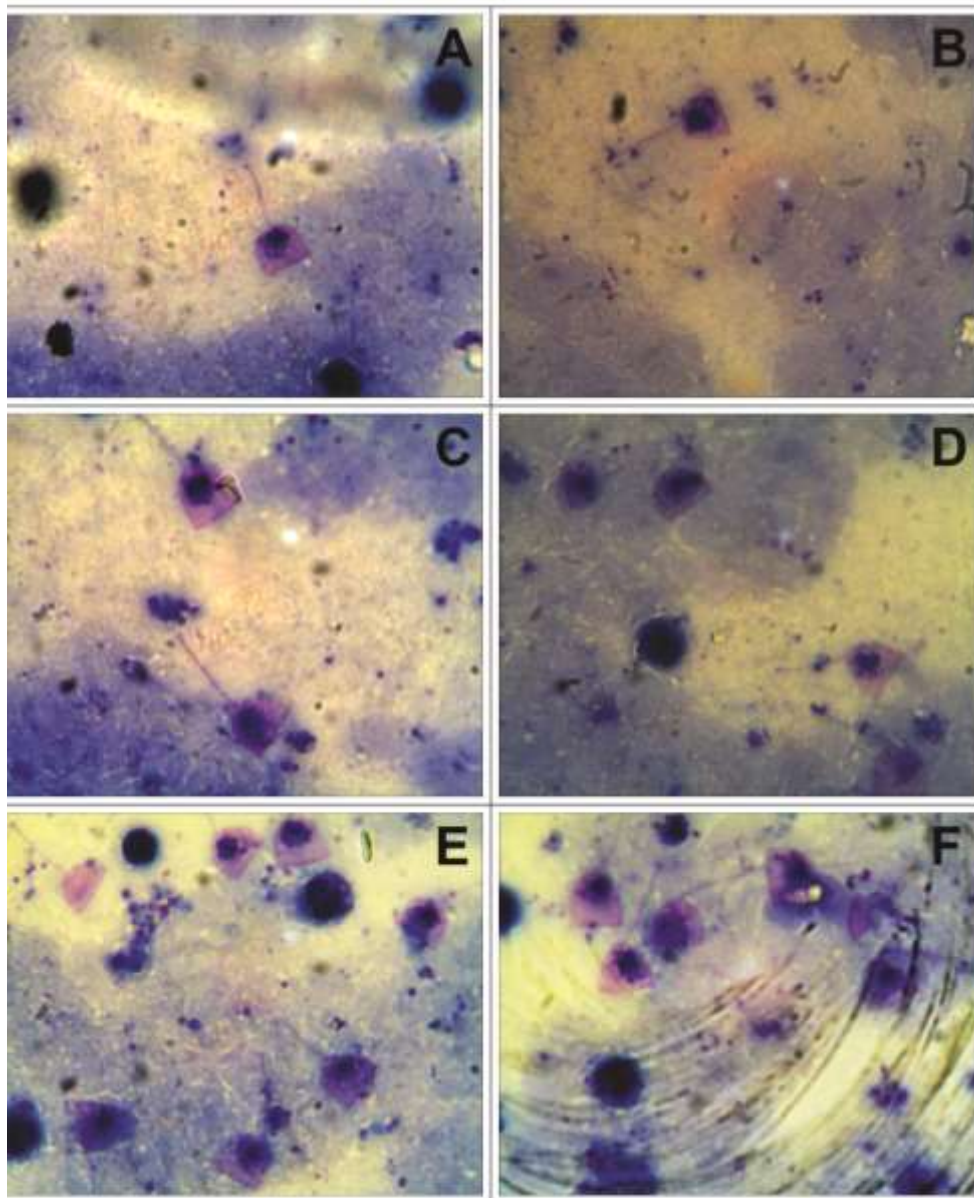
A careful examination of stained blood smear by light microscopy under oil immersion lens shows a "promastigote" form, single flagellated, cup shaped

protozoan in moderate numbers. This flagellate protozoan counted approximately  $2600 \pm 100$  in the single 20 cu mm blood smear. The body of the protozoan is covered by a thin periplast or pellicle which imparts the characteristic cup shape. The centrally lobulated nucleus is large  $3.8 \pm 0.4\mu\text{m}$  and bears a central nucleolus. The kinetoplast consists of a deeply stained parabasal body and an adjacent dot-like blepharoplast. The flagellum arises from the kinetoplast which is located above the nucleus. It emerges from the cell through a distinct notch of the pellicle. Length of flagella is

$14 \pm 2\mu\text{m}$ . The height of the protozoan is  $8.60 \pm 1.5\mu\text{m}$  and the width at the base is  $9.8 \pm 1.6\mu\text{m}$ . The circumference of the hemisphere /curve is  $22 \pm 2\mu\text{m}$ . Few empty cup-shaped pellicles with flagellum and smaller oval shaped individuals are also observed in the smear. (Figs.1-A-F). A comparative account with the haemoflagellates and their distinguishing characters is compared with these unknown protozoa in Table I. The blood samples of the patient collected after six months did not show presence of the protozoan.

**Table 1:** Comparative morphological forms of Haemoflagellates belonging to family Trypanosomatidae and the new unidentified protozoan.

Description of Human forms-	Genus		
	<i>Leishmania</i>	<i>Trypanosoma</i>	Unidentified Protozoan
Form	Amastigote	Trypomastigote	Promastigote
Shape	Ovale	Fusiform	Cup-shape
Flagellum	Absent	Anterior, anchored to kinetoplast	Anterior, anchored to kinetoplast
Kinetoplast	Present	Placed behind Nucleus	Placed ahead of nucleus
Nucleus	Present	Central	Central
Remark	Rhizoplast present	Undulating membrane present	Undulating membrane absent.



**Fig. 1.A-F.** Oil immersion (100 X 5) magnified photomicrograph of the blood smear showing presence of the unidentified protozoan haemoflagellate.

## Discussion

The flagellate protozoa that live in the blood and tissues of the human host all belongs to the family Trypanosomatidae. This family includes species that have a single flagellum, a nucleus and kinetoplast from which the flagellum arises. The detection of this new haemoflagellate raises many questions about its biology, which can be answered once we are able to analyze the living organisms. However, from this data it is clear that this haemoflagellate appears to be a new species and forms a new genus in the phylogeny of family Trypanosomatidae. Both genus of family Trypanosomatidae, *Trypanosoma* differs from this new form by its fusiform shape and the presence of undulating membrane while *Leishmania* remains oval as amastigote in human. Species of these genera at no stage ever exhibits the morphology and structure of this unidentified protozoon. Knowledge of the host range, vectors and prevalence of species in these loci is essential for epidemiological models and will aid predictions of disease (if caused) to both humans and livestock. This article confirms the presence of an unknown haemoflagellate protozoon in human.

**Conflicts of interest:** None.

## References

1. Bogitsh BJ, Carter CE, Oeltmann TN. Blood and tissue protozoa I: Human Parasitology. 3<sup>rd</sup> ed. Elsevier Academic Press, Oxford, UK, 2005.
2. Chakraborty P. Flagellate. Text book of Medical Parasitology. 2<sup>nd</sup> Ed. New central book agency. Kolkata, India, 2005.
3. Chris B. Parasitology-Haemoflagellates Part 1. Bacteriology 2: Available from: <http://prezi.com/psu88h9jfgv8/bacteriology-2-Parasitology-hemoflagellates-part-1>. 18 September, 2012.
4. Frederick L, James J. Cultivation of Clinically Significant haemoflagellates. Clinical Microbiology Rev. 2012; 15(3):374-389. Available from: <http://cmr.asm.org/content/15/8/374.full>.
5. Kristin M, Steve J. Animal and Human Parasite Images Last update, 2013. Available from: <http://www.k-state.edu/parasitology/625tutorials>. 15 Jan.
6. Smyth JD. Haemoflagellates. Animal Parasitology. 3<sup>rd</sup> Ed. Cambridge University press, UK, 1994.
7. National Vector Borne Diseases Control Programme Guideline- Current status of malaria microscopy and quality assurance. Operational Guidelines for Laboratory Technicians. NVBDCP Delhi India, 2007, pp 6-7. Available from: <http://nvbdc.gov.in/doc/sop-quality-assurance-microscopy.pdf>. 18 December.
7. Elsayed AN, Badawy AI, Sarhan M, Abdel-Aziz A. Haemonchus longistipes Railliet & Henry, 1909 (Nematoda, Trichostrongyloidea) from dromedary, Camelus dromedarius (Artiodactyla, Camelidae). Egypt: Prevalence and comparative assessment of vulvar morphology. Int. J. Biol. Res. 2019;4(3):107-12.