



Luxative injury managed by FRC splinting: Case report

Dr. Mrunal Bandiwar¹, Dr. Nikhil Marwah²

¹ Department of Pediatric and Preventive Dentistry, MGDCH, Jaipur, Rajasthan, India

² Professor and Dean Research, Department of Pediatric and Preventive Dentistry, MGDCH, Jaipur, Rajasthan, India

Abstract

Background: Luxation injuries are among the most common traumatic dental injuries in children and adolescents, often leading to damage of periodontal ligament and supporting structures. Timely diagnosis and appropriate management are critical to ensure optimal healing and tooth survival.

Case Report: This paper presents a case of traumatic luxation injury in a 7-year-old patient, successfully managed with functional repositioning and stabilization using a Fiber Reinforced Composite (FRC) splint. Clinical and radiographic evaluation confirmed the diagnosis and immediate repositioning followed by FRC splinting was carried out. Regular follow-ups demonstrated satisfactory periodontal healing, pulp vitality, and functional stability of the affected tooth.

Conclusion: FRC splints provide a simple, esthetic, biocompatible, and minimally invasive option for stabilization of luxated teeth. This case highlights the effectiveness of FRC splinting as a reliable management strategy for luxation injuries in pediatric patients, ensuring functional and esthetic rehabilitation with favorable prognosis.

Keywords: Luxation injury, FRC splinting, dental trauma

Introduction

Quality of life is significantly impacted by oral health; hence, oral health is crucial to overall health. Even though the burdens of dental caries and periodontal disease have historically been the two biggest global oral health burdens, recent research has shown that trauma to the teeth and jaws is also a major public health issue with an epidemiological component, has numerous clinical and financial implications, and significantly lowers the quality of life at every stage of life [1]. According to the American Academy of Pediatric Dentistry's policy on prevention of sports-related orofacial injuries, sports mishaps account for 10–39% of all dental injuries in children.² Dental trauma affects 16% to 40% of 6-year-olds in industrialized nations, 4% to 33% of 12- to 14-year-olds, approximately 15% of schoolchildren in various Latin American nations, and about 5% to 12% of 6- to 12-year-olds in the Middle East [3].

Oro-Dental Trauma (ODT) during sports is unavoidable, particularly among contact sports players and is more significantly seen in children between 6-12 years of age [4]. It impairs Oral Health-Related Quality of Life (OHRQoL), especially in adolescents, which should be seriously considered as it strongly influences adolescents' physical, emotional and psychological well-being [5, 6].

Dental injuries which occur during sports activities differ from other dental injuries, as it is possible to easily prevent, and there is also an option to diminish the frequency levels by the utilization of mouthguards⁷ and especially school-based mouthguard programs. This case report presents a unique case where the child presented with a hidden injury due to trauma in martial arts (Taekwondo) which could have been prevented had the mouthguard programme in the school was effectively followed.

Case Report

A 7 years old female patient was brought by her parents to the Department of Pediatric and Preventive Dentistry, MGDCH, Jaipur, about 2 days after a sports injury (initially

unknown to parents) that resulted in a dental trauma. The child had already been seen by a general dentist who prescribed antibiotic and anti-inflammatory medications. Past dental and medical history was evaluated upon which it was found that the patient had undergone pulp treatment followed by stainless steel crown with primary mandibular left first molar and multiple restorations in upper and lower jaw. However, the patient was in excellent health with no remarkable past medical history.

Extraoral clinical examination showed prominent swelling on right side of face and right upper lip (Fig. 1). Intraoral examination showed laceration of the maxillary labial mucosa at the level of maxillary right permanent central and lateral incisors, which had a lateral luxation and slight mobility. The right lateral incisor was displaced and both the teeth were tender on percussion (Fig. 2). Mandibular right central incisor showed gingival recession which was unrelated to trauma. Patient was unable to occlude and presented with difficulty in mastication.

An orthopantomogram examination was done which showed cervical fracture with maxillary right central incisor and no fractures involving crown or root or any injuries involving other teeth (Fig. 3). Hereafter, a CBCT examination was done as guided by the anticipated pain to rule out any minor fracture that might have been missed due to low resolutions of OPG. This examination revealed fracture of right nasal wall along with fracture lines at cervical margin for right central incisor. (Fig. 4.A,4. B).

Following the radiographic examination, patient was advised to consult an ENT surgeon for the treatment of right nasal fracture. The patient was then advised to wait and watch. The dental surgical treatment involved repositioning of teeth with finger pressure under local anesthesia. To ensure that the teeth had been correctly repositioned into the socket, an IOPA was taken. This was followed by splinting with (fiber reinforced with) composite resin (Fig. 5). Importance of maintaining good oral hygiene throughout the splinting period was explained to the parents. Patient was

kept on soft diet to avoid any further trauma and discomfort to the patient. According to AAE guidelines, splinting time was kept at 2 weeks and patient was recalled for a follow up visit.

Upon 2 weeks follow up visit, removal of splints was done (Fig. 6). Both the incisors presented with no mobility and satisfactory functional and esthetic demands. The patient was then explained about regular returning for clinical and radiographic follow ups.

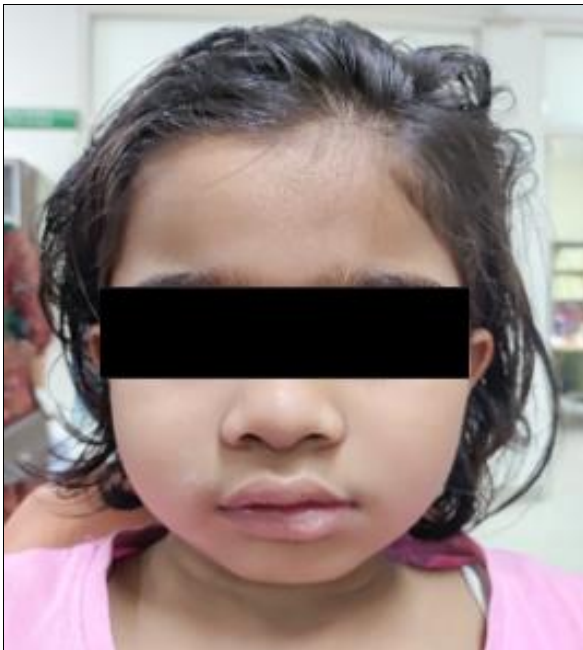

Fig 1: Extraoral examination showing prominent swelling on right side of face

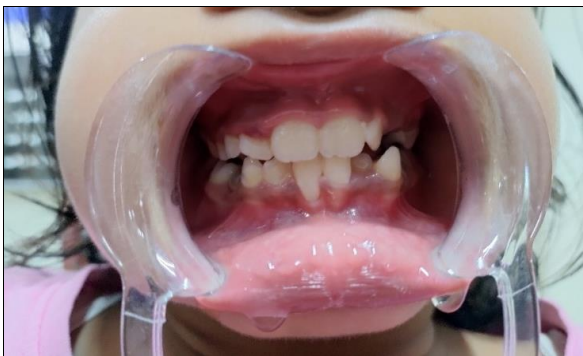

Fig 2: Intraoral examination showing displaced maxillary right central incisor

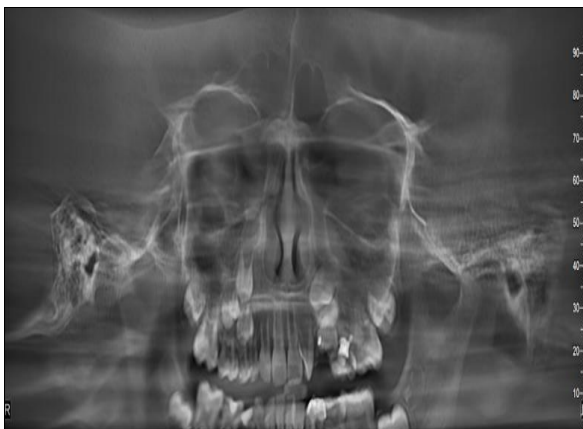

Fig 3: OPG showing cervical fracture with 11

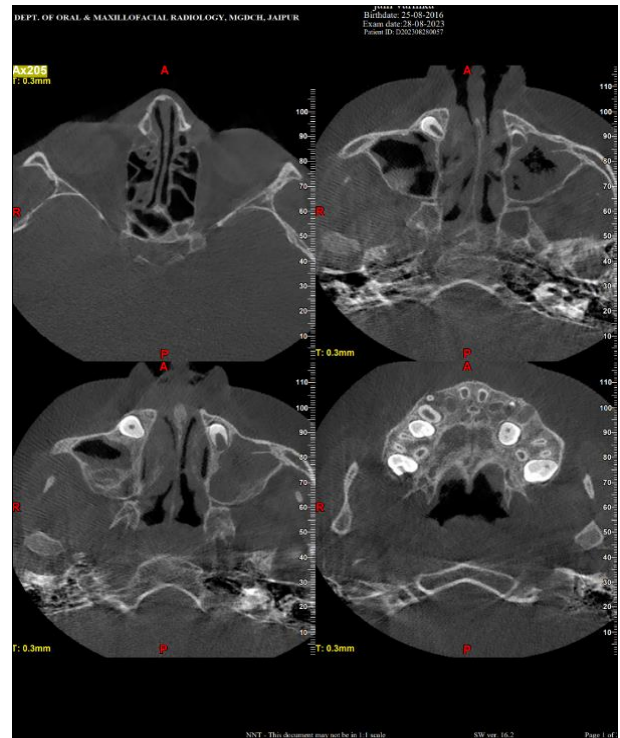


Fig 4.A

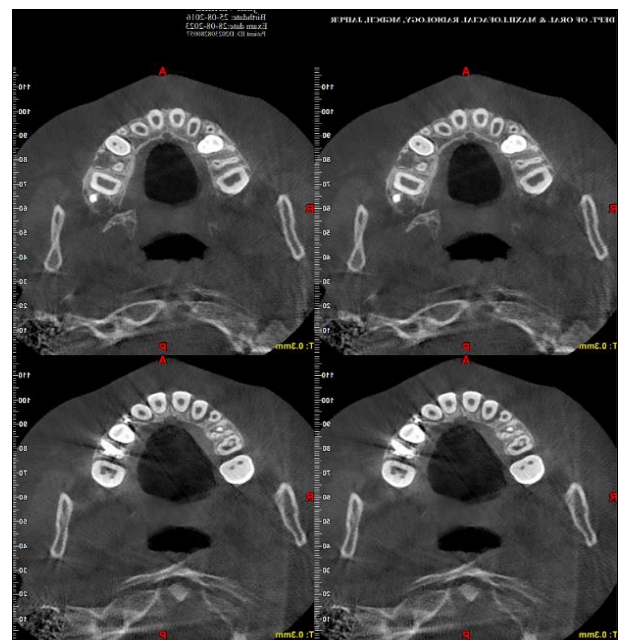


Fig 4.B: CBCT images showing cervical fracture with 11.

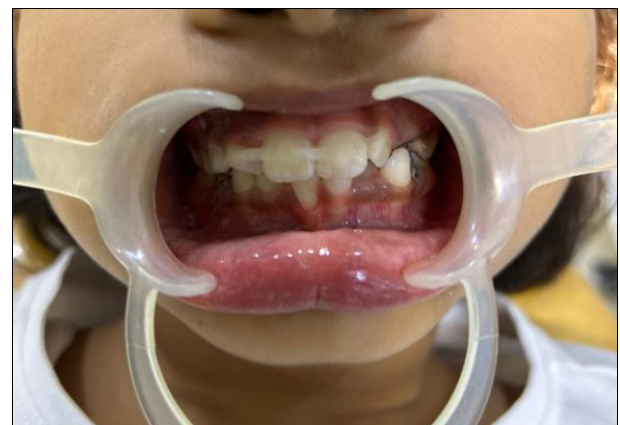

Fig 5: Follow up after 1 week

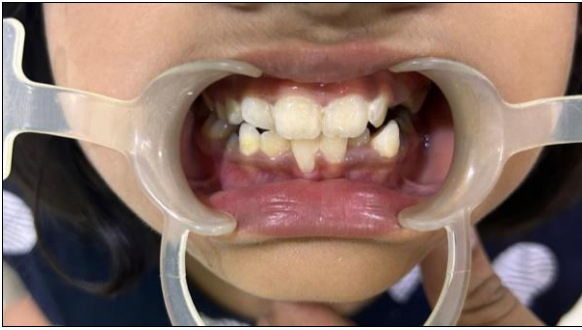

Fig 6: Removal of splints at follow up after 2 weeks

Discussion

Orofacial injuries, during sports not only have immediate deleterious effects but may also cause long standing injuries which may be more difficult for treatment. Rate of occurrence of sports-related oral injury varies comprehensively on the game played, level of competition, the participant's age, and sex [8]. The active participation of children in sports have increased over the years, especially in contact sports and so has the injury parameters. Injury during sports that involve physical contact between players, e.g., wrestling, boxing, basketball, and karate and are higher in comparison to non-contact sports [9].

Mouthguards play a vital role in preventing oro-dental injuries. They were first introduced by Woolf Krause, a London dentist, as a means of protecting boxers from lip lacerations (Reed 1894) [10]. Mouthguards are resilient intraoral devices that can be worn during contact sports to reduce the possibility of injury to the teeth and associated tissue [11]. The overall risk of an orofacial injury was reported as being 1.6 to 1.9 times higher when a mouthguard was not worn [12]. Three major types of mouthguards are currently available - readymade, boil-and-bite, and custom-made. Protective gears perform the following functions [1], reduce the impact of external force on the teeth & TMJ [2], provide a cushioning effect to the joint and peri-joint structures and [3] distribute forces to adjacent structures [13].

The present study emphasises the importance of diagnosis of hidden injury in contact sports like Taekwondo at school level. It also stresses upon the significance of use of protective aids like mouthguards which could have saved the child from trauma and subsequent emotional damage to child and patients.

A study conducted in Nigeria by Azodo *et al.* in 2011 [14] conducted a study regarding the mechanism of orofacial injury reported that being hit by the elbow of an opponent player contributed to 36.9% of injuries just as in our case, and fall and collision with another player contributed 29.2 and 13.6% of the injury, respectively [14]. Heintz WD in 1968 [15] and Kvittem B *et al.* in 1998 [16] reported that soft tissue lacerations, abrasions, tooth intrusions, avulsions, and crown-root fractures were the most commonly reported injuries of the orofacial region whereas zygoma, mandibular and alveolar fractures were comparatively less observed [15, 16]. Ranalli, in 2000 [17] gave a review that showed that correct and properly close-fitting protective aids like mouth guards, headgear, and helmets inhibit orofacial trauma, including dental injuries. So, the epidemiology of orofacial injuries is enduring a paradigm shift with satisfactory changes in protective aids, their usage, guidelines, and its regulations [17].

The most common types of injuries affecting periodontal tissues are luxations, whose prevalence varies from 15 to 61% [18]. The time interval elapsed since injury is very important because it influences the choice of treatment [18, 19]. According to Andreasen *et al* [18], repositioning of the dislocated teeth is more difficult after 48 h of the injury. In the present case, the repositioning was performed around 36 h after the injury, so treatment was possible and led to satisfactory results.

After lateral luxation, immediate reposition and stabilization of the teeth in their anatomically correct positions are essential to optimize healing of the periodontal ligament and neurovascular supply, while maintaining aesthetic and functional integrity [20]. The splinting period indicated for periodontal ligament therapy is 2-4 weeks as was followed in this case.

Mazzoleni S *et al.*, in an *in vitro* study, compared five different splint systems [polyethylene fiber-reinforced splint (Ribbond THM, Ribbond Inc., Seattle, WA, USA), resin splint (RS), wire-composite splint (WCS), button-bracket splint (BS) and titanium trauma splint (TTS) and concluded that the highest flexibility are the TTS and the Ribbond THM as they exhibit a lower energy variation needed for splint deformation compared with the other materials that were examined [21]. Fiber splints can provide increased stabilization of mobile or displaced teeth; and most importantly, they are aesthetically acceptable in young children. Moreover, the fixation procedure is very simple, and it does not cause any additional trauma to the surrounding soft tissues [22]. For this reason, fiber reinforced splints were used in place of wire-composite splints.

Although, mouthguards have been proven effective in reduction of oro-dental injuries during contact sports, some studies have enumerated some of their disadvantages. Glass *et al* [23] described the disadvantages associated with the use of mouthguards. These were mainly related to soft tissue reactions ranging from erythema and hyperkeratosis to ulceration. However, advantages of proper use of mouthguards far outweighs their disadvantages and hence is effectively advised.

Awareness amongst children and society in general can be brought about by various means like mouthguard programmes. Every sporting facility should have a dental surgeon on staff who will not only provide preventative treatment but will also consider therapeutic therapy. These actions will undoubtedly change how parents, sports coaches, and kids view using protective equipment, which will further contribute to lowering the number of orofacial injuries sustained while participating in sports.

References

1. Srilatha Y, Shekar BRC, Krupa NC. Effectiveness of school-based dental health education on knowledge and practices related to emergency management of dental trauma and tooth avulsion. An educational intervention study. *International Journal of Academic Medicine*,2021;7:39.
2. Padilha ACL, Constante HM, Fronza HP, *et al.* Orofacial trauma and mouthguard use in Brazilian rugby union players. *Dental Traumatology*,2021;37(1):53–57.
3. Nakre PD, Harikiran AG. Effectiveness of oral health education programs. A systematic review. *Journal of*

- International Society of Preventive and Community Dentistry,2013:3:103–115.
4. Razeghi S, Mohebbi SZ, Gholami M, Mashayekhi M, Maraghehpour B, Rahnama E. *et al.* Effect of two educational interventions on primary school teachers' knowledge and self-reported practice regarding emergency management of traumatic dental injuries. *BMC Oral Health*,2019;19:130.
 5. Das P, Mishra L, Jena D, Govind S, Panda S, Lapinska B. *et al.* Oral health-related quality of life in children and adolescents with a traumatic injury of permanent teeth and the impact on their families: A systematic review. *International Journal of Environmental Research and Public Health*,2022;19(5):3058.
 6. Comim LD, DallaNora Â, Knorst JK, Racki DNDO, Zenkner JEDA, Alves LS. *et al.* Traumatic dental injury and oral health–related quality of life among 15 to 19-year-old adolescents from Santa Maria Brazil. *Dental Traumatology*,2021;37(1):58–64.
 7. Glendor U. Aetiology and risk factors related to traumatic dental injuries—a review of the literature. *Dental Traumatology*,2009;25(1):19–31.
 8. Affairs AC. Using mouth guards to reduce the incidence and severity of sports-related oral injuries. *Journal of the American Dental Association*,2006;137(12):1712–1720.
 9. Levin L, Friedlander LD, Geiger SB. Dental and oral trauma and mouthguards use during sport activities in Israel. *Dental Traumatology*,2003;19(5):237–242.
 10. Kerr IL. Mouth guards for the prevention of injuries in contact sports. *Sports Medicine*,1986;3(6):415–424.
 11. American Academy on Pediatric Dentistry Clinical Affairs Committee, American Academy on Pediatric Dentistry Council on Clinical Affairs. Policy on prevention of sports-related orofacial injuries. *Pediatric Dentistry*,2008;30(S7):58–60.
 12. Hedge V, Kiran DN, Anupama A. Mouthguard in sports: A review. *Indian Journal of Stomatology*,2012;3:50–52.
 13. Singarapu R, Panneerselvam E, Balasubramaniam S, Nakkeeran KP, Ramanathan M, Raja VBK. *et al.* The role of mouthguards in preventing temporomandibular joint injuries during contact sports. A prospective study. *Frontiers in Dentistry*,2023;20:12.
 14. Azodo CC, Odai CD, Osazuwa PN, *et al.* A survey of orofacial injuries among basketball players. *International Dental Journal*,2011;61(1):43–46.
 15. Heintz WD. Mouth protectors. A progress reports. Bureau of Dental Health Education. *Journal of the American Dental Association*,1968;77(3):632–636.
 16. Kvittem B, Hardie NA, Roettger M, *et al.* Incidence of orofacial injuries in high school sports. *Journal of Public Health Dentistry*,1998;58(4):288–293.
 17. Ranalli DN. Prevention of sports-related traumatic dental injuries. *Dental Clinics of North America*,2000;44(1):35–51.
 18. Andreasen JO, Andreasen FM, Andersson L. Textbook and color atlas of traumatic injuries to the teeth. Oxford Blackwell, 2007.
 19. Dewhurst SN, Mason C, Roberts GJ. Emergency treatment of oral dental injuries: A review. *British Journal of Maxillofacial Surgery*,1998;36:165–175.
 20. American Academy on Pediatric Dentistry Council on Clinical Affairs. Guideline on management of acute dental trauma. *Pediatric Dentistry*,2008;30:175–183.
 21. Mazzoleni S, Meschia G, Cortesi R, Bressan E, Tomasi C, Ferro R, *et al.* *In vitro* comparison of the flexibility of different splint systems used in dental traumatology. *Dental Traumatology*,2010;26(1):30–36.
 22. Goswami M, Eranhikkal A. Management of traumatic dental injuries using different types of splints. A case series. *International Journal of Clinical Pediatric Dentistry*,2020;13(2):199–202.
 23. Glass RT, Conrad RS, Wood CR, Warren AJ, Kohler GA, Bullard JW, *et al.* Protective athletic mouthguards: Do they cause harm *Sports Health*,2009;1(5):411–415.