



Comparative study between Endoscopic septoplasty and conventional septoplasty

Mohammed Wafaie¹, Gamal Yousof², Mohammed Dahy³

¹⁻³ Department of Otorhinolaryngology, Faculty of Medicine, Al-Azhar University at Assiut, Egypt

Abstract

Objective: The aim of this study is to compare the postoperative outcome between endoscopic and conventional septoplasty patients.

Patients and Methods: This study was carried out on one hundred patients, fifty three males and forty seven females suffering from chronic nasal obstruction due to deviated nasal septum. The patients were selected from the E.N.T. Out-Patient Clinics of Al-Azhar University Hospital (Assiut) in the period from March 2016 to January 2019. The age of the patients ranged from sixteen years to forty three years. Half of the patients underwent endoscopic septoplasty group (A), while other fifty patients underwent conventional septoplasty group (B). Pre and postoperative evaluations were done in the form of history taking, clinical examination CT scan and nasal endoscopy. Endoscopic septoplasty was done for various types of septal deviations to show the technique and to compare efficacy with conventional septoplasty.

Results: It was found that endoscopic septoplasty is more effective than conventional septoplasty in treating nasal obstruction, correction of posterior deviations and septal spurs.

Conclusion: We conclude from this study that complaining deviated nasal septum can be treated by various techniques. Endoscopic septoplasty gives an excellent alternative to conventional head light one with many advantages as easy, safe, rapid, limited dissection of the flaps, good access to posterior and high deviations, good illumination and visualization less complications (odema, tear, perforation, hematoma crustation).

Keywords: endoscopy, endoscopic septoplasty, nasal septum

Introduction

Nasal obstruction is the most common complaint in rhinologic practice and deviated nasal septum is the most common cause of nasal obstruction. The evaluation of septal deviation causing nasal obstruction depends heavily on physical examination and imaging [1]. Endoscopy enables the surgeon to localize the spurs and remove them under direct visualization by performing an incision over the spur, thus minimizing surgical trauma, also enables management of other pathologies in the nasal cavity [2]. The progress of surgery on a deviated nasal septum witnessed great advances from radical removal of cartilage and mucosa and radical removal of cartilage only by submucous resection to the modern techniques of septoplasty [3].

Septoplasty is a commonly done for correction of deviated nasal septum either alone or combined with functional endoscopic sinus surgery (FESS) during the management of sinus diseases [4]. Conventional headlight septoplasty is the technique of choice by most Rhinologists around the world, however in recent year's indications and advantages of the endoscopic approach have been advocated by many authors [2, 5, 6, 7].

An ideal surgical correction of the nasal septum should satisfy the following criteria: a) Should relieve the nasal obstruction, b) Should be conservative, c) Should not produce iatrogenic deviations or perforation, d) Should not compromise the osteomeatal complex and e) Must have the scope for revision surgery, if required later. Also endoscopic aided technique was found to be more effective in relieving the contact areas and nasal obstruction [8] and simultaneous sinus surgery can be done without the fear of lateralization of the middle turbinate and consequent synechia formation

[9].

Patients and Methods

Every patients was submitted to the following:

History

History was taken including personal history, patient complaint, present history including asking patients about onset, course, duration of the complaint, nasal symptoms, history of trauma to the nose, the possible risk factors (immunosuppression, uncontrolled diabetes mellitus, smoking) associated symptoms, symptoms of complications, general medical condition, and other ENT symptoms, Past history of nasal disease, trauma, operations, drug intake, family history, other otorhinolaryngology disease and general disease as diabetes mellitus, hypertension.

Examination

General examination: Full otorhinolaryngology examination

A- Nasal examination

1. Anterior rhinoscopy using the thudicum nasal speculum.
2. Examination of the septum was done to detect if there is (Septal deviation, septal spur and caudal septal dislocation)
3. Preoperative and six months postoperatively diagnostic nasal endoscopy.

Nasal endoscopy (0° Karl Storz nasal endoscope) was used to examine the nose and nasopharynx after the use of local nasal decongestant and local nasal spray anaesthesia.

B- Ear examination: to assess tympanic membrane

abnormalities, drum was inspected in both ears and suction was carried out if necessary to establish tympanic membrane pathology.

C- Examination of the pharynx.

Preoperative routine investigations

Complete blood count, Bleeding time, Coagulation time, Prothrombin time, Partial prothrombin time, Random blood sugar, Serum creatinine ECG, Chest X-Ray.

Pre-operative Coronal C.T nasal and Paranasal sinus

A pre-operative routine coronal paranasal sinus CT was made to every patient to make sure about the type of the deviation and to exclude other pathological conditions of the nose e.g. hypertrophy of inferior turbinates, nasal polypsis, nasal masses and nasal synechia.

Post-operative Coronal C.T nasal and Paranasal sinus after six months.

Technique used in cases of endoscopic septoplasty

Position of the patient: The patients were placed in supine position with head end of table raised.

Infiltration

Infiltration of the nasal septum was done using 1: 100,000 adrenaline in saline solution. In cases of broadly deviated septum, infiltration was done at the caudal end of the cartilaginous septum and at bony crest in order to reach both sides of the septum. This injection was done using headlight for the anterior part of septum and endoscope for posterior parts. In cases of septal spur, we injected under endoscopic vision at the spur itself.

Incision

We used to make incision on the left side of the septum using fifteen N0.blade. A standard Killian incision was used except in cases of isolated septal spur, incision was done on the spur itself using sickle knife.

Flap elevation and dissection

After mucosal incision, mucoperichondrial flap elevation is performed with a Cottle elevator. Asuction elevator may be used as an alternative dissecting instrument to simultaneously clear any blood from the field of view during flap elevation. Further elevation was done using zero degree Karl Storz nasal endoscopy (4mm) held in left hand, keeping the tip of the endoscope between mucoperichondrial flap and the septal cartilage. The right hand was used for instrumentation. Flap elevation should be done at the correct cleavage plane to minimize bleeding.

The endoscope was found to be more useful in this regard, especially in post-traumatic cases where proper cleavage is difficult. Exposure was limited to target area. The septal cartilage is then incised posterior to the mucosal incision. The contralateral mucoperichondrial flap elevation is then performed under endoscopic vision. Flap elevation is continued bilaterally until complete extent of septal deformity has been dissected. At this time, a pair of angled scissors is introduced and used to cut through septal cartilage on adirection which is parallel to and at least 0.5 cm posterior to the nasal dorsum.

We removed only the obstructing cartilage leaving at least caudal and dorsal struts to maintain support of nasal dorsum and columella. The cartilage is removed with Luc's forceps

or a Ballenger's swivel knife under endoscopic vision. We can use also punches or forceps. Any deviated bone only in the vertical plate of ethmoid is then removed under endoscopic vision with punches or forceps. Large pieces of excised cartilage and bone are saved in saline solution in order to reinsert one of them between 2 flaps at the end of surgical procedure.

If the maxillary crest is deviated, we elevated flaps of the maxillary crest and vomer under endoscopic vision. We remove it with gouge and hammer under endoscopic vision if it is deviated. In cases of subluxated cartilage from the crest, the excess cartilage inferiorly was shaved using No. 15 Rounded blade Bard Parker knife. Then, it was repositioned over the crest to prevent a supra tip deformity. If there was associated vomerine spur or crest, it was resected. In cases of spur only, incision was done directly over the spur under endoscopic vision especially for posterior spurs. Exposure was done by elevating the flaps with sharp end of Cottle elevator Patients and methods 89 superiorly and inferiorly. It was removed either by straight biting forceps, microdebrider (using a bone cutting blade) or osteotome.

At the end of operation, we suture 2 flaps with 4-0 absorbable sutures. Also, if there was any mucosal tear it was sutured with 4-0 absorbable sutures. We restricted septal splinting only to cases in whom a flap tear had occurred. Then both nasal cavities were packed with Vaseline or merocel packs. The time of each operation was calculated, blood loss also was calculated where suction bottle was emptied before operation, accurate calculation of any amount of saline used for washing of operative field during surgery. So, the amount of pure blood loss was the amount in the suction bottle during the whole surgical procedure minus the calculated amount of saline used for irrigation plus the difference in swap weighting pre and post-operative. Postoperatively, all patients were viewed in the outpatient clinic. Once weekly for the 1st month then every 2 weeks for 3 months and monthly till the end of follow up period after 6 months. Statistical analysis of the collected data was done using Statistical package for social science (SPSS). Statistical methods included descriptive method (mean, standard deviation, frequency distributon) and significance tests (t=test) and analysis of variance (ANOVA). The significance will be adjusted when P value equal 0.05 or less.

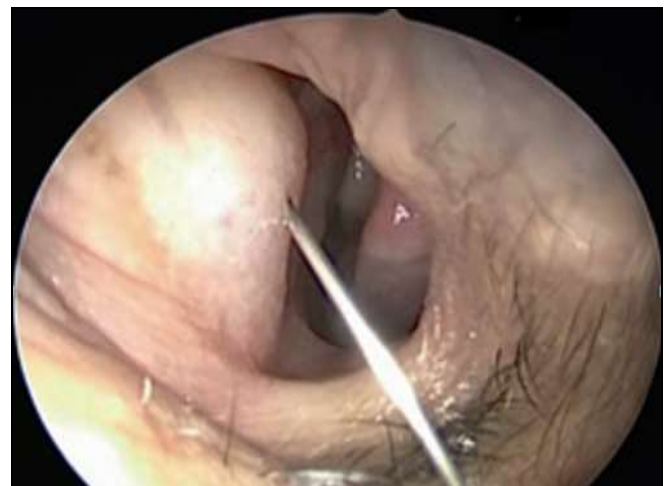

Fig 1: Left nasal cavity, Infiltration of the deviated nasal septum using 1:100,000 adrenaline in saline solution.

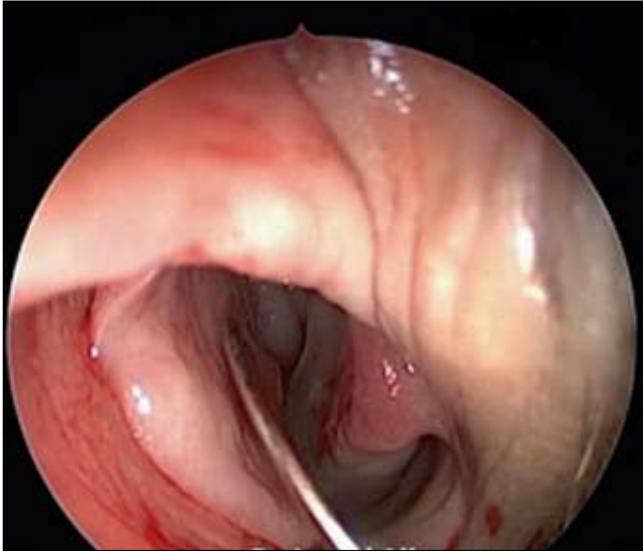


Fig 2: Endoscopic view at the end of operation

Results

This study included one hundred patients presenting to the E.N.T outpatient clinic at Al-Azhar University Hospital (Assiut) complaining of chronic nasal obstruction due to deviated nasal septum. The nasal obstruction was usually associated with other symptoms e.g. headache, snoring, postnasal discharge or hyposmia. There were septal deviation to the right side of the nose in twenty nine patients, to the left side of the nose thirty eight patients and to both sides in thirty three patients for a period ranged from one year to five years. Half of the patients underwent endoscopic septoplasty group (A), while other fifty patients underwent conventional septoplasty group (B).

The age in the conventional group varied from 16 to 40 years with a mean of 29.6 years. The age of the endoscopic group varied from 18 to 43 years with a mean of 30.4 years. We didn't find any significant difference in pre-operative results between both groups as regards age, sex, side of nasal obstruction, and types of septal deformities (Septal spur, anterior septal deformity or posterior septal deformity). So, the pre-operative circumstances were similar between both groups; consequently any expected difference in the post-operative results would depend mainly on the surgical technique used in each group. As regard the duration of each procedure in our study, endoscopic septoplasty consumed 25 minutes in isolated septal spur up to 55 minutes in broadly based deflections or more than one septal deformity. But in conventional septoplasty, it is ranged from 40 to 70 minutes which means that the duration of operation is shorter by endoscopy.

Blood loss during operation was variable in group A from 30- 65ml with a mean of 41.25 ± 13.46 ml, but in group B it was ranged from 40-90 ml with a mean of 59.5 ± 14.5 ml. Concerning intra operative blood loss it was statistically significant difference between the two groups as P value was < 0.0001

As regard nasal packing in group (A) fifty cases were

packed (100%).the same was in group (B) fifty cases were packed (100%). As regard Intraoperative flap tear occurred in seven cases (14%) in group (A), while it occurred in fifteen cases (30%) in group (B), it was statistically insignificant difference between two groups as P- value was 0.0534 early postoperative complications during first week all patients were hospitalized for 24 hours. Group (A): five patients (10%) had epistaxis upon removal of the pack, forty eight hours postoperatively that was controlled by insertion of ephedrine packs for few minutes. And after one week post operatively five patients (10%) had experienced mild pain and discomfort. Three patients (6%) had experienced smell of bad odour. Two patient (4%) had synechiae. Neither septal haematoma nor was septal perforation or CSF leakage diagnosed. Group (B): Eight patients (16%) had epistaxis upon removal of the pack Forty eight hours postoperatively, it was controlled by insertion of ephedrine pack for few minutes and after one week post operatively mild pain and discomfort were experienced in ten patients (20%). Eight patients (16%) had a smell of bad odour due to infection and crustations. Six patients (12%) had synechiae.

Two cases (4%) of septal haematoma, was diagnosed but incision and drainage was done and the patient was improved. One patient (2%) with septal perforation was diagnosed. No CSF leakage was encountered. No death was happened. Chi square test shows no significant difference in early postoperative complication during 1st week in both groups. Postoperative evaluation after six months: Repeated regular examination was done in the outpatient clinic of Al-Azhar University Hospital (Assiut) for six months. Postoperative evaluation was done after six months. Objective assessment: Endoscopic examination and C.T: Nasal endoscopic examination was done frequently for follow up for each patient. The nasal endoscopic findings on last available follow up (after six months) were: In group (A): Persistent posterior deviation was present in three patients (6%), three patients (6%) had nasal crustations, persistent contact with turbinates was present in one patient, spurs was present in one patient, nasal synechiae was present in one patient. Nither septal haematoma nor perforation was present. In group (B): Persistent posterior deviations were present in thirteen patients (26%) and spurs were present in eight patients (16%).

Nasal crustations were present in seven patients (14%). Persistent contact with turbinates was present in ten patients (20%). Nasal synechiae was detected in three patients (6%). septal perforation was present in one case (2%), while no cases with septal hematoma were recorded. Concerning posterior deviation, spur and persistent contact with turbinates all represented statistically significant difference between the two groups as P-value was < 0.05 while, septal hematoma, septal perforation, crustations and synechiae were statistically insignificant differences as P value was > 0.05 . Chi square test showed significant difference in improved nasal obstruction between both groups as p-value 0.0012, but there was no significant difference between both groups in snoring, headache, post-nasal discharge (PND), hyposmia and sneezing.

Table 1: Nasal endoscopic findings at last available follow up after Six months.

		Group				p. value
		Endoscopic septoplasty		Conventional septoplasty		
		N	%	N	%	
Anterior deviation	Yes	-	-	-	-	-
	No	50	100	50	100	
Posterior deviation	Yes	3	6	13	26	0.006
	No	47	94	37	74	
Spur	Yes	1	2	8	16	0.0144
	No	49	98	42	84	
Synechiae	Yes	1	2	3	6	0.307
	No	49	98	47	94	
Persistent contact with turbinates	Yes	1	2	10	20	0.004
	No	49	98	40	80	
Hematoma	Yes	0	0	0	0	-
	No	50	100	50	100	
Perforation	Yes	0	0	1	2	0.4966
	No	50	100	49	98	
Crustations	Yes	3	6	7	14	0.182
	No	47	95	43	86	

Table 2: Comparison of the subjective results between both groups (six months post-operative).

Symptoms (NO. of cases)		Endoscopic septoplasty		conventional septoplasty		P-value	Significance
		Improved	Not improved	Improved	Not improved		
Nasal obstruction (n=50/50)	NO.	45	5	30	20	0.0012	This result was significant at p < .05.
	%	90	10	60	40		
Snoring (n=20/25)	NO	16	4	13	12	0.0512	This result was not significant at p < .05.
	%	80	20	52	48		
Headache (n=30/37)	NO	22	8	22	15	0.234	This result was not significant at p < .05.
	%	73.3	26.6	59.4	40.5		
PND (n=18/23)	NO	12	6	13	10	0.508	This result was not significant at p < .05.
	%	66.6	33.3	56.5	43.4		
Hyposmia (n=12/10)	NO	8	4	5	5	0.428	This result was not significant at p < .05.
	%	66.6	33.3	50	50		
Sneezing (n=8/10)	NO	5	3	5	5	0.595	This result was not significant at p < .05.
	%	62.5	37.5	50	50		

Discussion

Nasal septal deviations play a critical role in nasal obstruction symptoms, aesthetic appearance of the nose increase nasal resistance and sometimes snoring [10]. Endoscopic techniques for correction of septal deviations makes it easier for surgeons to see tissue planes. Also, because the technique is minimally invasive, it offers a better way to treat isolated septal spurs. Furthermore, the technique gives surgeons improved access to a deviation that is posterior to a septal perforation. Additionally, the endoscopic approach makes it possible for many people to simultaneously observe the procedure on a monitor making the approach useful in a teaching setting [11].

One consideration or relative contraindication for using the endoscopic technique is a caudally located septal deformity. In such cases the telescope does not afford a significant benefit until flap dissection is carried more posteriorly [12]. Concerning age and sex distribution this study showed that: Group A: Included fifty patients: twenty three males (46%) and twenty seven females (54%) their ages ranged from eighteen to forty three years with a mean age of 30.4±7.2 years. Group B: Included fifty patients: thirty males (60%) and twenty females (40%) their ages ranged from sixteen to forty years with a mean age of 29.6±6.9 years.

In this study, we didn't find any significant difference in the preoperative results between both groups as regards age, sex, and types of septal deviations indicating that any expected difference between the postoperative results of

both groups was not dependent on these factors. These results agree with a study by Leena *et al* in 2011 [6] as regard age incidence, but disagree with the study as regard sex incidence. Majority of the patients presented with deviation to the left side (36%) followed by (34%) the cases having deviation to the right and (30%) of Patients had bilateral deviation. This results agree with a study by Daghistani *et al* in 2002 who said that incidence of DNS was more to the left side(55.6%). Nasal obstruction was the main symptom in all cases (100%), in the study by Iqbal SM *et al* 2013 [14], they found that majority of the, patients presented with the nasal obstruction (90%).

The results of this study agree with that concluded by Nayak *et al* in 1998 [8] concerning postoperative incidence of persistent deviation and contact areas was much lower following endoscopic correction compared to that following the conventional septal surgery. Kaushik *et al* [7] reported more improvement in the endoscopic group concerning posterior deviations and spurs as compared to the conventional group although their results were statistically insignificant and this disagree with the results of this study. This study agree with Hwang *et al* in 1999 [15] that the major relative contraindications for endoscopic septoplasty were two folds: 1-When the deviations involves a significant caudal deflection, 2- When significant associated external deviations were present for which aseptorhinoplasty approach should be indicated.

Conclusion

We conclude from this study that that two procedures were suitable to correct septal deviations. But endoscopic septoplasty was superior to conventional septoplasty in: cases of isolated septal spur, as we made incision on the spur itself. So less time consuming during operation, less blood loss and less morbidity. Also it was superior in preventing occurrence of persistent posterior deviations and spurs

Recommendation

From this study we advise the use of endoscope as a standard method for correction of different types of septal deviations such as isolated septal spur and posterior deviations due to its advantage over conventional septoplasty method regarding efficacy, less incidence of complications accompanied with conventional method such as: a) Persistent nasal obstruction, b) Bleeding, c) Septal hematoma, d) Synechia, e) Septal Perforation, f) Anosmia and g) Crustation

Reference

1. Dinis PB, Haider H. Septoplasty Long term evaluation of results. American Journal of Otolaryngology. 2002; 23(2):85-90.
2. Raynor E. Powered endoscopic septoplasty for septal deviation and isolated spurs. Arch Facial Plast Surg, 2005.
3. Al-Shehri AM, Amin HM, Necklawy A. Retrospective study of endoscopic nasal septoplasty. Biomed Res-India. 2013; 24(3):337-340.
4. Singla K, Singh B, Bhagat S. endoscopic septoplasty: prospective study in 50 cases of DNS. Clin Rhinol An int J. 2013; 6(2):92-95.
5. De Sousa A. Inciartef Land Levine H. Powered endoscopic nasal septal surgery. Acta Med Port. 2005; 18:249-56.
6. Jain L, Jain M, Chouhan AN. Conventional Septoplasty verses Endoscopic Septoplasty: A Comparative Study. People's Journal of Scientific Research. 2011; 4(2):24-28.
7. Kaushik S, Vashistha S, Jain NK. Endoscopic vs conventional septoplasty a comparative study. Clin Rhinol An int J. 2013; 6(2):84-87.
8. Nayak D, Balakrishnan R, Murthy D. An endoscopic approach to the deviated nasal septum –a preliminary study. Journal of Laryngology and Otology. 1998; 112:934-939.
9. Gupta M, Motwani G. Comparative study of endoscopic aided septoplasty and traditional septoplasty in posterior nasal septal deviations. Indian Journal of Otolaryngology and Head and Neck Surgery. October–December. 2005; 57(4):309-311
10. Hsia JC, Camacho M, capasso R. snoring exclusively during sleep, anewly described respiratory pattern during sleep), sleep and Breathing. 2014; 18(1):159-164
11. Guindi Sherif S, Mostafa Hany S, Fawzy Tamer O. Endoscopic-assisted septoplasty versus traditional septoplasty: assessment by the NOSE scale Egypt Otolaryngol. Year. 2016; 32(1):26-31.
12. Lor A. lemonier. Endoscopic septoplasty, operative technique otolaryngology, <http://dx.doi.org>
13. Daghistani KJ. Nasal Septal Deviation in Saudi Patients: A Hospital Based Study J KAUMed Sci.

2002; 10:39-46.(1422 AH/

14. Iqbal SM, Hussain SI, Bhojani MJ. A Comparative Study of Endoscopic Verses Conventional Septoplasty an Analysis of 110 Cases Pak J Surg. 2013; 29(3):220-3.
15. Hwang PH, McLaughlin RB, Lanza DC, Endoscopic Septoplasty Indications, technique and results. Otolaryngol Head Neck Surg. 1999; 120:678-682.