



IJMIRD 2015; 2(1): 440-442  
www.allsubjectjournal.com  
Received: 11-12-2014  
Accepted: 13-01-2015  
E-ISSN: 2349-4182  
P-ISSN: 2349-5979  
Impact factor: 3.762

**M.V.S.R. Vineet Kumar**  
BDS, FAGE,  
Narayana Dental College,  
Nellore, India

**Deepthi Gulivindala**  
BDS,  
Narayana Dental College,  
Nellore, India

## Esthetic management of anterior teeth with ceramic veneers

**M.V.S.R. Vineet Kumar, Deepthi Gulivindala**

### Abstract

Very minimal preparation with enamel preservation offer best results in esthetic dentistry. Composite restoration offer repairable option for a smile treatment plan. Sometimes, it may be preferable to extend the veneer preparations beyond the contact points toward the palatal surface, to hide the margins of the restoration. The case report presented describes minimal invasive treatment of four upper incisors with laminate ceramic veneers. A step-by-step procedure is proposed for diagnostic evaluation, mock-up fabrication and trial, teeth preparation and impression, and adhesive cementation. Patients have the chance to evaluate the function, esthetics and phonetics before the permanent restoration.

**Keywords:** Laminates, porcelain, minimal tooth preparation, conservative

### 1. Introduction

There are many new treatment plans which are being indicated for misaligned anterior teeth. There are various ways to treat cosmetic dental problems depending upon the problem per se. Diastema, tooth size discrepancy, discolorations, staining, fractures in teeth, endodontic treatment, and smile designing are some of the reasons for which patient seek esthetic dental treatment. Some restorative techniques are conservative such as use of adhesives and lasers while others are subtractive methods.

New ceramic and composite materials have conservative treatments of anterior teeth [1, 2]. Indirect additive veneering are introduced as an alternative to full-coverage crowns. The concept of minimal-preparation [3] has followed the development of appropriate enamel bonding procedures. The color and integrity of dental tissue substrates to which veneers will be bonded are important for clinical success [4]; using additional veneers with a thickness between 0.3 mm and 0.5 mm, 95% to 100% of enamel volume remains after preparation and no dentin is exposed [6]. For example, when the colour of the existing substrate (the patient's teeth) is acceptable, thin porcelain laminate veneers (0.3–0.7 mm) may be suitable. A number of clinical studies have concluded that bonded laminate veneer restorations delivered good results over a period of 10 years and more [7, 8]. Some indications for no-preparation veneering include erosion, incisal edge microfractures, corrections for short and small crowns and alterations in the superficial enamel caries. For many years, full-coverage crowns were indicated in this situation, but this treatment option is now considered invasive because of the need to remove tissue. The term “minimally invasive” is also used to describe full veneers that wrap around the teeth, although such restorations actually cover the buccal and palatal surfaces of the prepared teeth.

The case report presented here describes minimal invasive technique used for closure of gaps between anterior teeth using porcelain laminates. This veneering procedure is most acceptable and shows best esthetic results.

### 2. Case Report

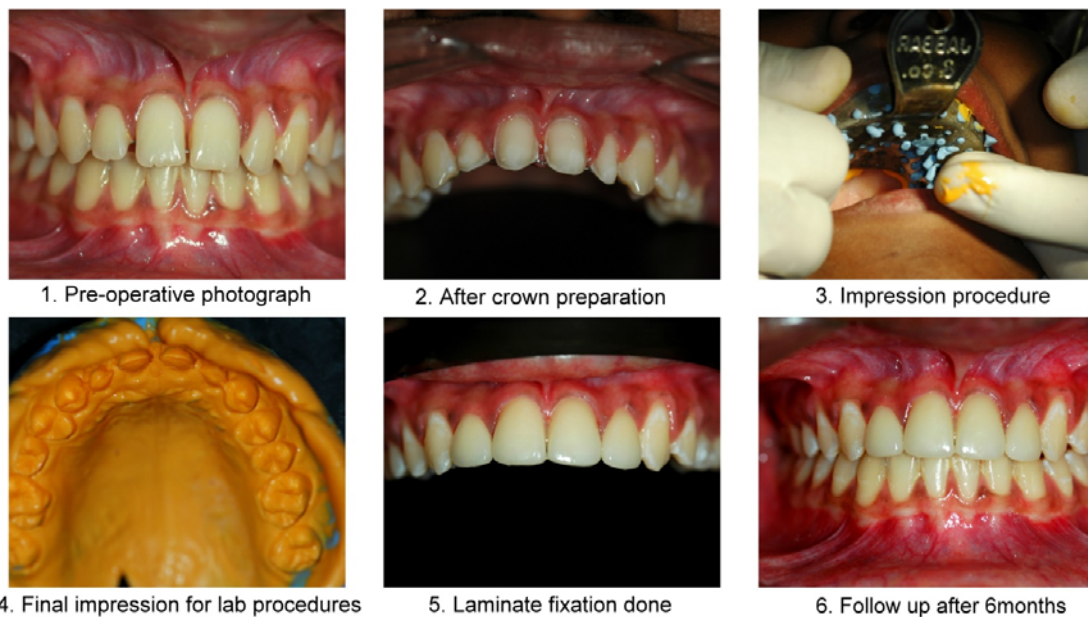
A 24-year-old female patient was concerned about her misaligned teeth. Another dentist had placed composite restorations several years previously to fill the gaps between her teeth. She reported that after 6months of the restoration process, it turned black and looked artificial.

During the first appointment, digital photographs and radiographs were obtained, and alginate impressions were made. After relevant data were collected and description of the clinical procedures had been presented, the treatment options were discussed with the patient [9, 10]. After all the explanation and she did not want to sacrifice sound enamel.

**Correspondence:**  
**M.V.S.R.Vineet Kumar**  
BDS, FAGE,  
Narayana Dental College,  
Nellore, India

However, she had certain expectations about the final position, colour and surface texture of the teeth. Proper shade selection was done and photographs were taken for perfect shade match. During her second appointment the following comprehensive treatment plan was adopted: remove resin composite restorations, make impressions, prepare the tooth

for laminates and temporary crowns were given. On her final visit, shade match was confirmed with the patient and then etching, bonding and adhesive cementation of the laminates were done and then performed finishing and polishing of the bonded porcelain restorations.



The procedure for cementation was performed on two teeth at a time starting at the midline. The prepared teeth were etched using 37% Phosphoric Acid (Meta Etchant- 37, Meta Biomed Co. Ltd, Korea) for 15 seconds. On air drying bonding agent (Meta P & Bond, Meta Biomed Co Ltd, Korea) was applied & light cured for 10 seconds. Dual cure composite crown and bridge luting agent (Duolink, Bisco, USA) was used for cementation. The laminates were spot cured for 5 seconds initially. Excess cement was removed with explorer and then complete curing was done for 20 seconds. On completion of the cementation procedure, the occlusion was checked in centric and eccentric positions for interferences. The high points were removed and polished. Follow up is being done every 6months and patient has no complaint with the laminates.

### 3. Discussion

Gaps between teeth in adults are called diastemas and may simply be a result of having too much space in the jaw for the size of the teeth. Usually, these spaces are most noticeable when they are between the two upper front teeth, but they can appear between any two teeth. Normally, these spaces are not a cause for alarm, but they should be evaluated by a dentist to ensure that your bite has not been affected. Treatment planning for diastema correction include orthodontic closure, restorative therapy, surgical correction or multidisciplinary approach depending upon the cause of diastema (Dlugokinski *et al*, 2002). The restorative closure of diastema can be achieved by using any of the techniques mentioned; direct composite veneers, indirect composite veneers, porcelain laminate veneers, all ceramic crowns, metal ceramic crowns and composite crowns ((Dlugokinski *et al*, 2002; Rammelsberg *et al*, 2005). Various clinical studies have shown that the survival rate for bonded porcelain laminate veneer restorations is more than 90% over 10 years of clinical service. In those studies, the failures

reported were either cohesive ceramic fractures (the majority) or failures of the adhesive between the cement and the tooth surface [11]. Adhesive-related failures could be attributed to the extent of tooth preparation. Particularly with deep preparations in dentin, less adhesion can be expected relative to enamel. In fact, the bond strength of composite cement to enamel is in the range of 40 MPa, sometimes exceeding the cohesive strength of enamel itself. Failure of the adhesive between cement and enamel was rarely observed [11]. In addition to fractures, other types of failure, such as microleakage and debonding, have been reported. Even, if the laminates fail in the long run, the conserved tooth can still be treated with a full crown restoration. Porcelain laminate veneers offer a predictable and successful treatment modality that preserves a maximum of sound tooth structure. An increased risk of failure is present only when veneers are partially bonded to dentin. The estimated survival probability of porcelain laminate veneers over a period of 10 years is 91% (Dumfahrt & Schäffer, 2000).

### 4. Conclusion

Ceramic veneers will provide successful esthetic and functional long-term service for patients. Color match, porcelain, and marginal integrity are mostly satisfactory. Care needs to be taken during tooth preparation and particularly during the luting phase to ensure maximal results are obtained for the patient. This is a conservative procedure with maximum patient satisfaction.

### 5. References

1. Ferracane JL, Resin composite—state of the art, Dental Materials 2011; 27(1):29–38. View at Publisher. View at Google Scholar. View at Scopus.
2. Peumans M, Van Meerbeek B, Lambrechts P, Vanherle G. Porcelain veneers: a review of the literature, Journal of Dentistry 2000; 28(3):163–177. View at Scopus.

3. Magne P, Hanna J, Magne M. The case for moderate, “guided prep” indirect porcelain veneers in the anterior dentition. The pendulum of porcelain veneer preparations: from almost no-prep to over-prep to no-prep, *European Journal of Esthetic Dentistry* 2013; 8(3):376-388.
4. Azer SS, Rosenstiel SF, Seghi RR, Johnston WM. Effect of substrate shades on the color of ceramic laminate veneers, *Journal of Prosthetic Dentistry* 2011; 106(3):179–183. View at Publisher View at Google Scholar. View at Scopus
5. LeSage B. Establishing a classification system and criteria for veneer preparations, *Compendium of Continuing Education in Dentistry* 2013; 34(2):104–117. View at Scopus
6. Layton DM, Walton TR. The up to 21-year clinical outcome and survival of feldspathic porcelain veneers: accounting for clustering, *The International journal of prosthodontics* 2012; 25(6):604–612. View at Scopus
7. Layton DM, Clarke M, Walton TR. A systematic review and meta-analysis of the survival of feldspathic porcelain veneers over 5 and 10 years, *The International journal of prosthodontics* 2012; 25(6):590–603. View at Scopus
8. Layton D, Walton T. An up to 16-year prospective study of 304 porcelain veneers, *International Journal of Prosthodontics* 2007; 20(4):389–396. View at Scopus.
9. Fradeani M. *Esthetic rehabilitation in fixed prosthodontics. Esthetic analysis: a systematic approach to prosthetic treatment.* Chicago (IL): Quintessence; 2004; 1:42-67.
10. Devigius A. Treatment goal for the anterior segment – functional reconstruction or smile design. In: Roulet JF, Kappert HF, editors. *Statements: diagnostics and therapy in dental medicine today and in the future.* New Malden: Quintessence, 2009, 81-7
11. Friedman MJ. A 15-year review of porcelain veneer failure – a clinician’s observation *Compend Contin Educ Dent* 1998; 19(6):625-8.